

Case Report

Non-operative Korean Medicine Treatment for Four Patients with Failed Back Surgery Syndrome after Spinal Fusion Surgery : A Retrospective Case Series

Seo Young Hoon¹, Lee Jeong Ryo¹, Lee Sang Min¹, Kim Min Chul¹, Kim Yu Jong¹, Hong Je Rak¹,
Kim She Young², Seo Young Woo², Kim Ji Su², Park Han Sol³, Lee Min ho⁴,
Kim Tae Hun⁵, Kim Kiok⁶

¹Department of Rehabilitation, Mokhuri Neck & Back Hospital, Seoul, Republic of Korea

²Department of Acupuncture & Moxibustion Medicine, Mokhuri Neck & Back Hospital

³Department of Science in Korean Medicine, Graduate School, Kyung Hee University

⁴Department of Clinical Korean Medicine, Graduate School, Kyung Hee University

⁵Department of Korean Medicine Clinical Trial Center, Kyung Hee University

⁶Department of Spine Center, Mokhuri Neck & Back Hospital

Objectives: The purpose of this study was to report Four cases of Failed Back Surgery Syndrome (FBSS) patients after spinal fusion surgery who showed significant improvement in pain and function with Complex Korean medical treatment.

Methods: This study was a retrospective observational study. We reviewed medical records of Four patients with lumbar pain or radiating leg pain, who have received spinal fusion surgery in the past. All Four patients took complex treatments of Mokhuri Neck and Back hospital which involves Acupuncture, Pharmaco-acupuncture, Gangchuk herbal medicine, Chuna and Physical therapy during about four-week of admission treatment. Visual Analogue Scale (VAS), Oswestry disability index (ODI), Pain Free Walking Distance (PFWD) scores were assessed before and after treatments.

Results: The average of hospitalization period was 28.5 days. Mean VAS scores decreased from 6.5 to 2.3, Oswestry Disability Index (ODI) scores decreased from 56.25 to 38.25 and Pain Free Walking Distance (PFWD) also improved from 10m to 166.6m.

Conclusion: This study implies that a combination of Korean medical treatments might be effective in relieving pain, and improving the functional status of FBSS patients. Further studies are needed to fully understand the mechanisms underlying the effects.

Key Words : Failed Back Surgery Syndrome, Spinal Stenosis, Spondylolisthesis, Korean traditional medicine

Introduction

Failed Back Surgery Syndrome (FBSS) is diagnosed in patients who have persistent back pain despite having undergone spinal surgery of any type, including

discectomy, laminectomy, or fusion¹). In a broad sense, FBSS is a term embracing a constellation of conditions that describes persistent or recurring Low Back Pain (LBP), with or without sciatica following one or more spinal surgeries²).

• Received : 13 January 2016

• Revised : 17 June 2016

• Accepted : 17 June 2016

• Correspondence to : Tae-Hun Kim

Korean Medicine Clinical Trial Center, Kyung Hee University

23, Kyungheedaero-ro, Dongdaemun-gu, Seoul, Korea

Tel : +82-10-6532-5524, E-mail : rockandmineral@gmail.com

Failure of such surgeries is not rare. One study by Cauchoix et al evaluated the failure of surgery for 6%⁴⁾. Another study by Javid et al reports a surgical failure rate as approximately 30%⁵⁾.

Overall, The failure rate in spinal surgery is 15%, which suggests considerable potential risk of spinal surgery⁶⁾. In addition, the success rate for secondary surgery after the initial failed surgery is also very low. Secondary surgery after failed spinal fusion showed a 50-60% fail rate and a third or fourth operation each showed to have a 50-60% and 70-80% fail rate. As the number of surgical procedures increased, the chance of having successful outcomes decreased³⁾.

Considering high failure risk of spinal surgery, patients with FBSS are generally recommended to receive initial conservative treatment and consider surgical treatment only if conservative treatment shows to have no effect.

Among various types of conservative treatments, Korean medical treatments such as bee venom acupuncture and pharmaco-acupuncture have been reported to be a helpful intervention to the FBSS patients⁷⁻⁸⁾. Generally, Herbal medicine, acupuncture, manual therapy (such as Chuna) and physiotherapy are used simultaneously for this condition in the current clinical practice of Korea but there is no research on the benefit and harm of complex interventions available.

From these perspectives, we are reporting Four FBSS patients who expressed recurrent pain after fusion surgery due to Adjacent Segment Disease (ASD) and showed clinically significant improvements after about One month of complex Korean medicine treatment at Mokhuri Neck & Back Hospital.

Methods

This study was an retrospective observational study based on the medical records of patients that received admission treatment at Mokhuri Neck &

Back Hospital. All patients had received spinal fusion surgery of lumbar vertebra and showed recurrent lower back pain and leg pain. The data collected was from Jan. 2014. to Dec. 2015.

All patients that participated in the Research trial agreed on the usage of their medical records for research purposes

The patients were told to notify medical officials if any adverse events were to occur.

1. Treatment

All patients received acupuncture treatment, oral administration of herbal medicine, pharmaco-acupuncture treatment, relaxative chuna therapy, and physical therapy for an average of Four weeks.

(1) Acupuncture treatment.

Each patient received acupuncture treatment (2 sessions a day, 1 session on Sunday, total 13 sessions a week).

GV3, BL23, BL24, GB30 were treated in all patients, other acupuncture points were selected based on the symptoms of each patient by a Korean Medical Doctor.

0.25*40mm disposable stainless steel acupuncture needles (Dong Bang Co., Korea) were used for treatment. Acupuncture treatment time was about 15 minutes.

Everyday besides Sunday, patients received Two acupuncture sessions, One was given with electro-acupuncture and the other without electrical stimulation. On Sundays patients would only receive acupuncture without electrical stimulation

(2) Oral administration of herbal medicine

Each patient received oral administration of Gangchuk herbal decoction, a Herbal medicine three times a day, 30 minutes after each meal.

Gangchuk herbal decoction is composed of *Geranium thunbergii* which is known for its anti-nociceptive and anti-inflammatory effects, and *Sorbus commixta* which inhibits osteoclastogenesis and stimulates chondrogenesis along with many

other herbs⁹⁾ that in Korean medicine make the muscles and bones strong in order to reduce pain and strengthen the weakened muscle.

Other components of Gangchuk herbal decoction are *Eucommiae cortex*, *Achyranthis radix*, *Cibotii rhizoma*, *Saposhnikoviae radix*, *geranii herba* and *Acanthopanax cortex*.

(3) Pharmaco-acupuncture treatment

Each patient received Hwangryunhaedok-tang pharmacoacupuncture injection treatment which consisted of *Coptidis rhizoma*, *Scutellariae radix*, *Phellodendri cortex*, and *Gardeniae fructus* extracts.

Hwangryunhaedok-tang pharmacoacupuncture solution (1-2 cc; Korean Pharmacoacupuncture Institute, Korea) was injected at the same site of acupuncture site subcutaneously.

Hwangryunhaedok-tang is a Korean medical prescription composed of *Coptidis rhizoma*, *Scutellariae radix*, *Phellodendri cortex*, and *Gardeniae fructus* extracts. Hwangryunhaedok-tang is distilled and used after many processes including cooling, filtration, pH regulation and high pressure sterilization.

Pharmacoacupuncture needles are 26-gauge insulin syringes and each patient received treatment once a day.

(4) Relaxative Chuna

Relaxative Chuna is manual Korean manipulation techniques which relaxes low back muscles including *Latissimus dorsi*, *Rhomboid*, *Quadratus lumborum*, *Gluteus medius&minus*, *paraspinal muscles*, etc.

The patient laid prone on the ErgoStyle™ FX.-5820 table(Chattanooga Group. USA). Using the COX maneuver and manual manipulation, the lumbar spines were flexed and extended to 5~15 degrees 20 times a minute. This was to relieve the lumbar muscles and pelvic muscles. Each session lasted 15 minutes each and was held out five times a week.

(5) Physical therapy

Each patient received physical therapy 6 times a week (patients didn't receive physical therapy on

Sunday).

Physical therapy was consist of microwave therapy (5 minutes), Muscle low frequency therapy (10 minutes), Electromagnetic therapy (10 minutes) and Hot pack (10 minutes).

Physical therapy was applied on both Erector spinaes, Gluteus muscles, Iliolumbar ligaments and Sacroiliac ligaments.

2. Assessment

Visual Analogue Scale (VAS), Functional status of patient, Pain Free Walking Distance (PFWD) was used for assessment of patient's condition during the admission period of each patient.

(1) VAS

VAS is a visual scale showing the degree of pain felt by the patient. A point is drawn on a 10cm long line where one end represents no pain and the other the worst pain possible to imagine. One is unable to use this score to compare between patients, however it is useful in recording the course of pain levels throughout a single patient. VAS scores were checked every week.

(2) Functional status of patient

Oswestry Disability Index (ODI) is an index to rate the degree of disability in the Lumbar region. It was first introduced in 1980 and is made up of 10 categories and 6 responses for each category. Each category is scored between 0 and 5. All ten scores answered are then added and divided by the total score possible (if all categories were answered, 50) then multiplied by 100. This result in a score ranging from 0~100. A higher score indicates a higher rate of disability.¹¹⁾ The ODI was completed two times during the treatment, Admission date and discharge date.

(3) PFWD

PFWD is the distance the patient is able to walk free of any back pain or radiating leg pain. The PFWD was measured every week in this study.

Case series

1. Patient 1 (Female, 77 years old)

- C/C
 - a. LBP
 - b. Both buttock/leg pain
- O/S
 - a. April 2014
- Past History
 - L4-5 Fusion Surgery (8 years ago)
- Family History
 - None specific
- Social History
 - None specific
- Present illness

Received L4-L5 lumbar spinal fusion surgery 8 years ago (Figure 1). Received N-block treatment, April 2014 due to LBP and both buttocks/leg pain. Treatment was unsuccessful and persistent pain was

experienced. HIVD in the L3 level was found in a Lumbar MRI test taken May 20 2014. Analgesics were taken afterwards but due to constant pain was admitted to Mokhuri Neck & Back Hospital July 1st, 2014. Patient was taking DM medication.

- Findings
- Diagnosis
 - a. Lumbar Disc protrusion of L2-3, L3-4
 - b. Post Fusion surgery state of L4-L5
- Hospitalization period
 - July 1, 2014 ~ July 26, 2014 (26 days)
- Progress(Table 1)

2. Patient 2 (Female, 77 years old)

- C/C
 - a. LBP
 - b. Both buttock/leg numbness (Lt>Rt)
- Past History
 - L4-5 Fusion Surgery (8 years ago)

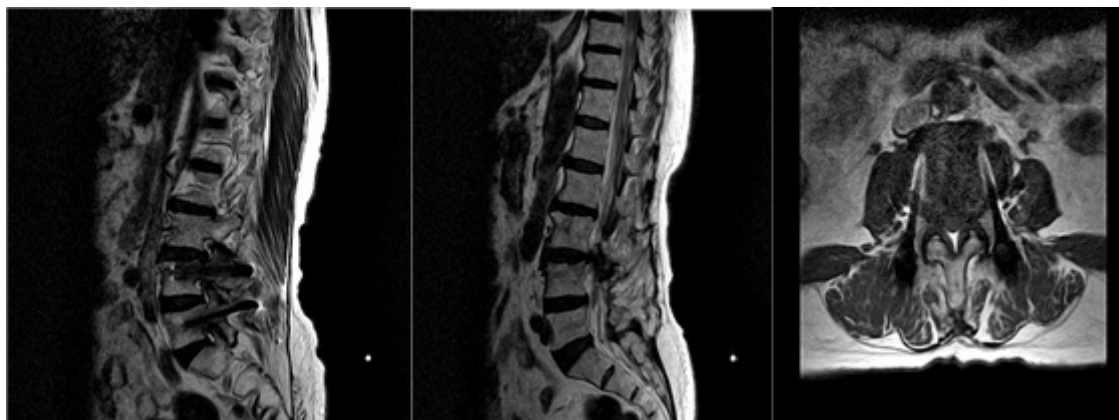

Fig. 1. 2014/05/20, Sagittal image, L3-L4 axial image

Table 1. Progress of Patient 1. *D/C = Discharge

	July 1 2014 (1st week)	July 8, 2014	July 15, 2014	July 26, 2014 (D/C date)
VAS	8	4	3	2
ODI	67			36
PFWD	0	40	100	160

- Family History
None specific
- Social History
None specific
- Present illness

Received lumbar spine Fusion surgery 8years ago. Recurrent pain became worse in March 2014, March 22, patient took a Lumbar MRI and was recommended surgery but the patient refused. Instead, underwent neuroplasty, failed to relieve of pain and started Per Oral (PO) medication. Visited Mokhuri Neck & Back Hospital July 24th 2014. Admitted July 28th 2014. Patient was on HTN medication.

- Findings
- Diagnosis
 - a. Post Fusion Surgery state of L4-5
 - b. Spondylolisthesis of L4 on L5, Grade 1.
 - c. Spinal stenosis of L4-5
 - d. Broad-based disc protrusion of L5-S1

- Hospitalization period
July 28, 2014 ~ August 23, 2014 (27 days)
- Progress(Table 2)

3. Patient 3 (Female, 55 years old)

- C/C
 - a. Rt LBP
 - b. Rt leg radiating pain&numbness
- Past History
L4-5 Fusion Surgery (6 years ago)
- Family History
None specific
- Social History
None specific
- Present illness

Received Lumbar fusion surgery 6years ago. Attended to a local OS whenever pain was felt and received Physical therapy and PO medication. Pain intensified December of 2014 and visited Mokhuri

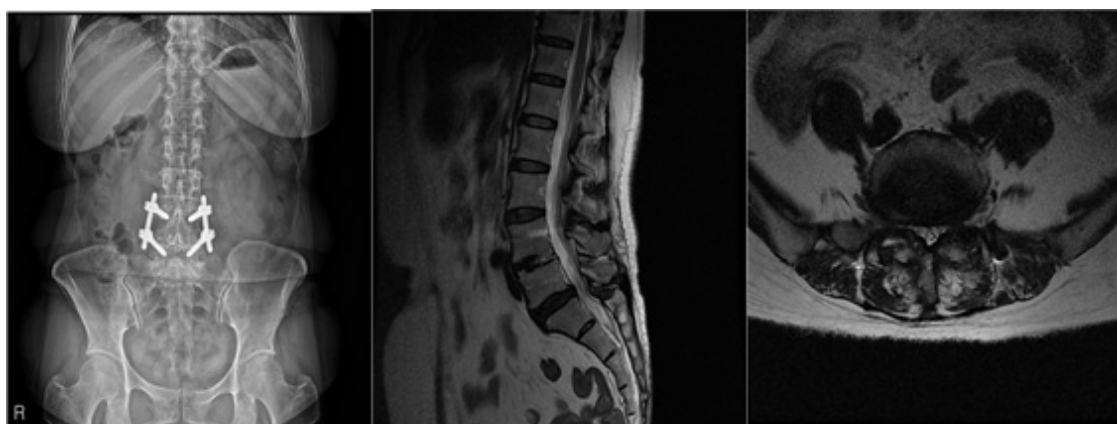


Fig. 2, 2014/03/22, Lumbar x-ray ap, sagittal image, L5-S1 axial image

Table 2. Progress of Patient 2, *D/C = Discharge

	July 28 2014 (1st week)	August 4, 2014	August 11, 2014	August 23, 2014 (D/C date)
VAS	3	3	2	0
ODI	56			34
PFWD	40	100	140	180

Neck & Back Hospital. Unable to extend L-spine and walked with a limp due to pain. Unable to sit still for 5 minute due to pain.

- Findings(Figure 3)
- Diagnosis
 - a. L2-3 - Right central disc protrusion with annular tear
 - b. L3-4 - Diffuse bulging disk
- Spondylolisthesis of L3 on 4, grade 1
- Facet joint arthrosis at both sides --> Narrowed spinal canal, suggested
- c. L4-5 - Spinal fusion with pedicle screw state
- d. L5-S1 - Central disc protrusion
- e. Degenerative disc change at L2-3 to L5-S1
- Hospitalization period
February 24, 2014 ~ March 22, 2014 (28 days)
- Progress(Table 3)

- C/C
 - a. LBP
 - b. Both buttock pain
 - c. Both leg radiating pain
- Past History
Fusion surgery (3 years ago)
- Family History
None specific
- Social History
None specific
- Present illness
Symptoms first appeared in 2009, after L-spine MRI test patient was diagnosed with Lumbar stenosis. Received Fusion surgery in L4-5 levels in 2012. Patient experienced continuous pain and in Feb. 2014 took another L-spine MRI exam and was diagnosed with ASD and spondylolisthesis grade 2. Received nerve block numerous times but failed to be relieved of pain and visited Mokhuri Neck &

4. Patient 4 (Female, 75 years old)

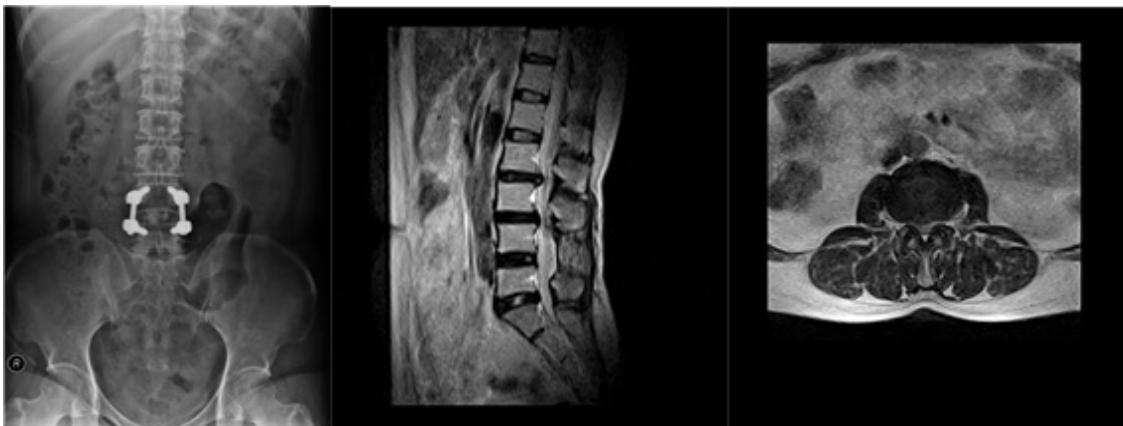


Fig. 3. 2014/02/25, Lumbar x-ray ap, sagittal image, L2-L3 axial image

Table 3. Progress of Patient 3. *D/C = Discharge

	February 24 2014 (1st week)	March 3, 2014	March 10, 2014	March 17, 2014	March 22, 2014 (D/C date)
VAS	8	4	3	3	3
ODI	56				40
PFWD	0	30	70	120	180

Back Hospital.

Patient was taking HTN and DM medication

Both leg pain and tension was felt on first step of walking and had trouble standing still.

- Findings(Figure 4)
- Diagnosis
 - a. L1-2 - Rt subarticular disc protrusion
 - b. L2-3 - Lt subarticular disc protrusion
 - c. L3-4 - Spondylolisthesis L3 on L4, Grade 1, spinal stenosis
 - d. L4-5 - modic type 2 change of end plate, post fusion surgery state.
- Hospitalization period
 - September 7, 2015 ~ October 9, 2015(33 days)
- Progress(Table 4)

Disc herniation or spondylolisthesis, recurrent LBP and leg pain occurred. All 4 patients had pain or gait disturbance that restricted the patients from everyday activities. All patients received admission treatment and the average hospitalization period was 28.5 days. Average VAS scores were 6.5 before treatment and reduced to 2.3 after treatment (Figure 5) ODI scores were average 56.25 before admission treatment and showed improved to 38.25 after treatment (Figure 6). The PFWD also showed improvement from an average of 10m before treatment to an average of 166.6m (Figure 7). Minor adverse events such as slight bleeding or bruises occurred after acupuncture treatment. But no severe adverse events such as a drop in functional status or intensified pain were reported

Results

The 4 patients mentioned above all went through Spinal Fusion surgery. After surgical treatment,

Discussion

The results of this Retrospective Case Series

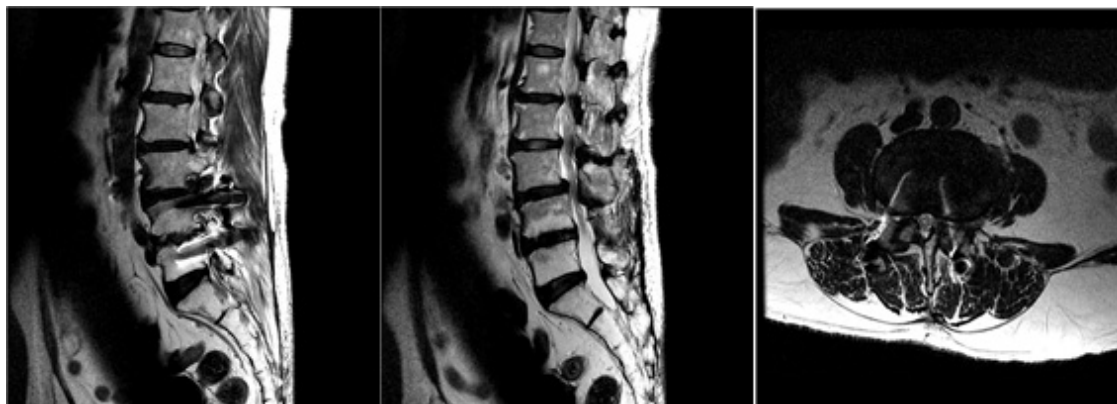

Fig. 4. 2014/02/25, Lumbar MRI sagittal image, L3-L4 axial image

Table 4. Progress of Patient 4. *D/C = Discharge

	September 7 2015 (1st week)	September 14, 2015	September 21, 2015	September 18, 2015	October 9, 2015 (D/C date)
VAS	7	7	6	4	4
ODI	46				43
PFWD	0	0	20	80	140

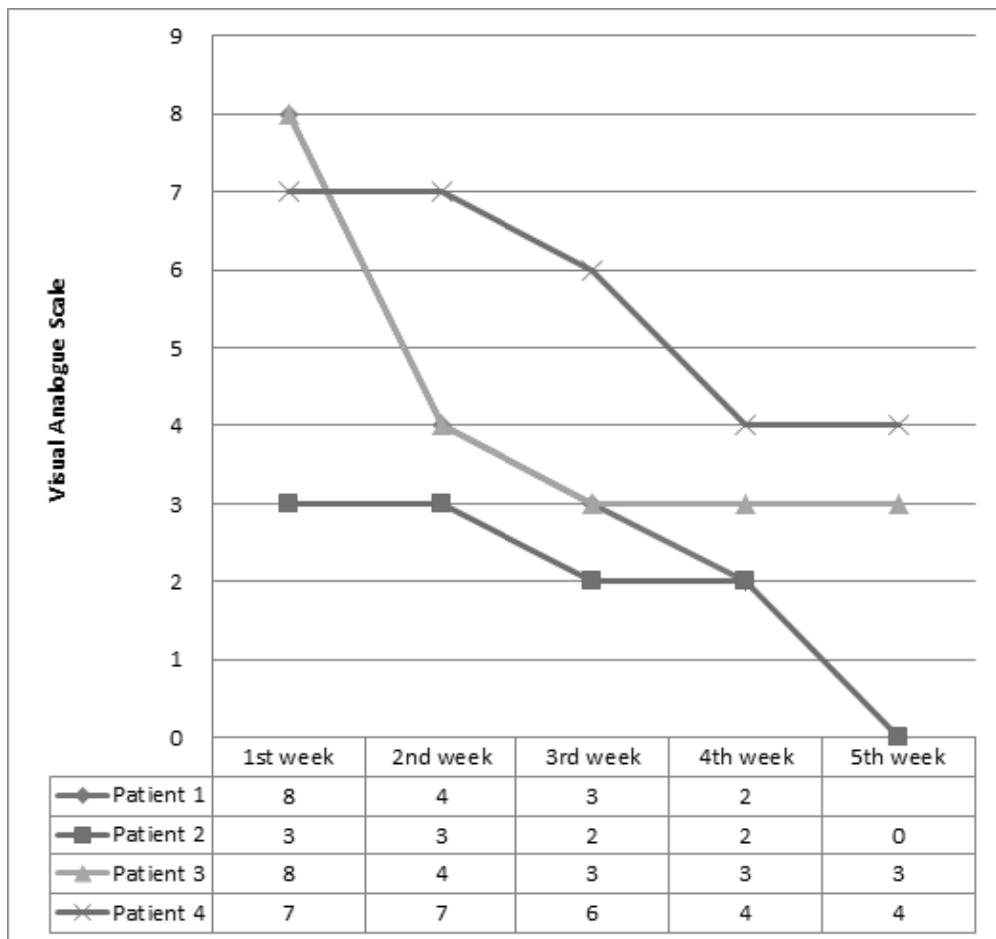


Fig. 5. Comparison of VAS score

shows that with about 1 month (average 28.5days) of Complex Korean Medical Treatment.

The mechanism of this complex intervention is not established currently. However, each intervention has therapeutic effect and all individual effect might be summed up for relieving symptoms of FBSS. The effects of acupuncture on LBP can be found in multiple previous studies and its clinical efficiency is acknowledged among many practitioners.¹²⁻¹⁵⁾ Brinkhaus B, et al. reported that the group which had received acupuncture had a significantly higher analgesic effect compared to the non-acupuncture

group¹³⁾. Zhao, Z. Q. reported that manual acupuncture stimulated A β -fibers as well as a part of A δ -fibers which results as an analgesic effect¹⁵⁾. These analgesic natures of acupuncture are seemed to be the reasons for reducing pain in FBSS patients. Pharmacopuncture treatment used in this study was initially designed to combine the effects of acupuncture and herbal medicine. Hwangryunhaedok-tang pharmacopuncture solution was used in this study. Hwangryunhaedok-tang pharmacopuncture is used in many painful diseases and there are reports of its anti-inflammatory actions.¹⁶⁾ The

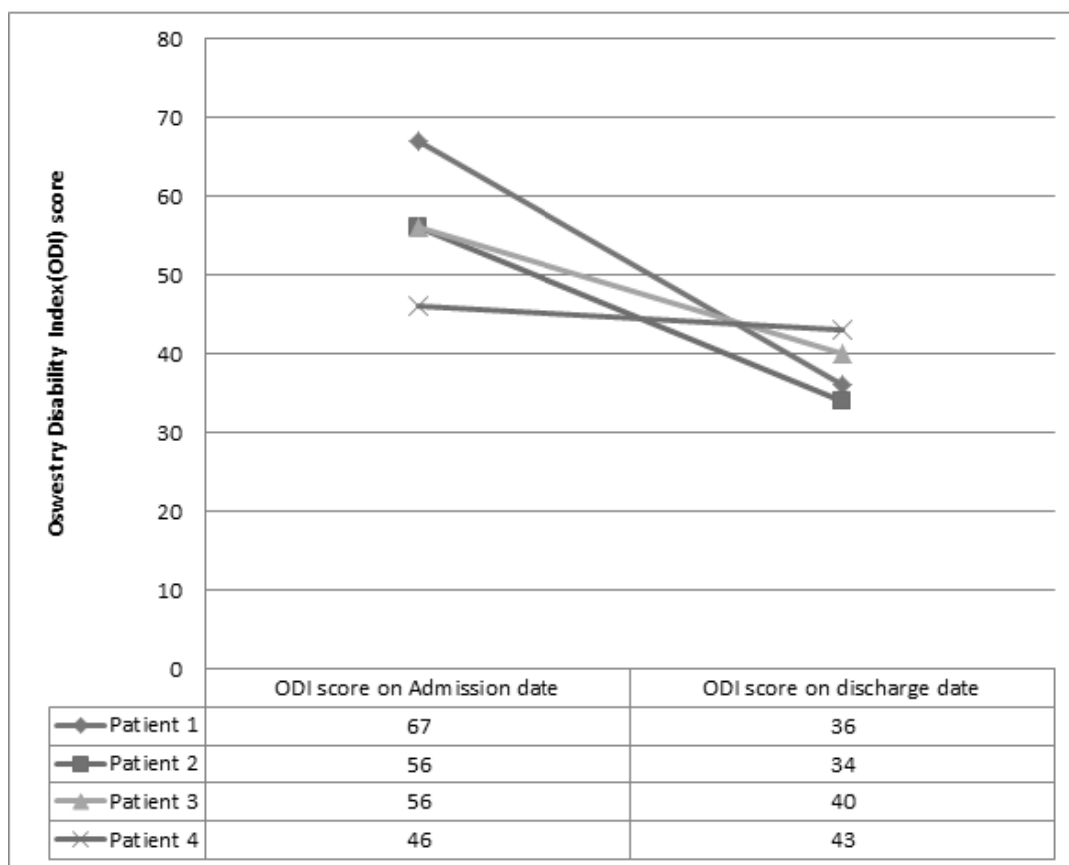


Fig. 6. Comparison of ODI score

underlying reason for pain in FBSS can originate from many reasons. Besides from problems involving the surgical procedure itself or misdiagnosis, Common reasons include inflammations in the arachnoid or chronic inflammations related to surgery which interfere with the mobility of the nerve root itself causing pain¹⁷⁾¹⁸⁾, and epidural fibrosis¹⁹⁾. Which can explain why Hwangryunhaedok-tang pharmacopuncture is effective. The clinical evidence of Chuna treatment has been suggested: 19 papers about Chuna treatment were published in the peer-reviewed journals after 2010. In acute LBP patients a maximum of 4 weeks of treatment and in chronic LBP patients a range of 8~12 weeks of treatment showed to be

effective.²⁰⁾ Relaxative Chuna used in this study relieves stress in the muscles of the lower back including the Latissimus dorsi, Rhomboids, Quadratus lumborum, Gluteus medius & minimus, and the paraspinal muscles. By relieving stress in the lower back is thought to help reduce pain.

Ganchuk-tang, a herbal medicine for this condition include several medicinal herbs that in Korean medicine make the muscles and bones strong in order to reduce pain and strengthen the weakened muscle and each of them has therapeutic effect on FBSS patients

Although the results of this study are positive, there are several limitations. First of all we were

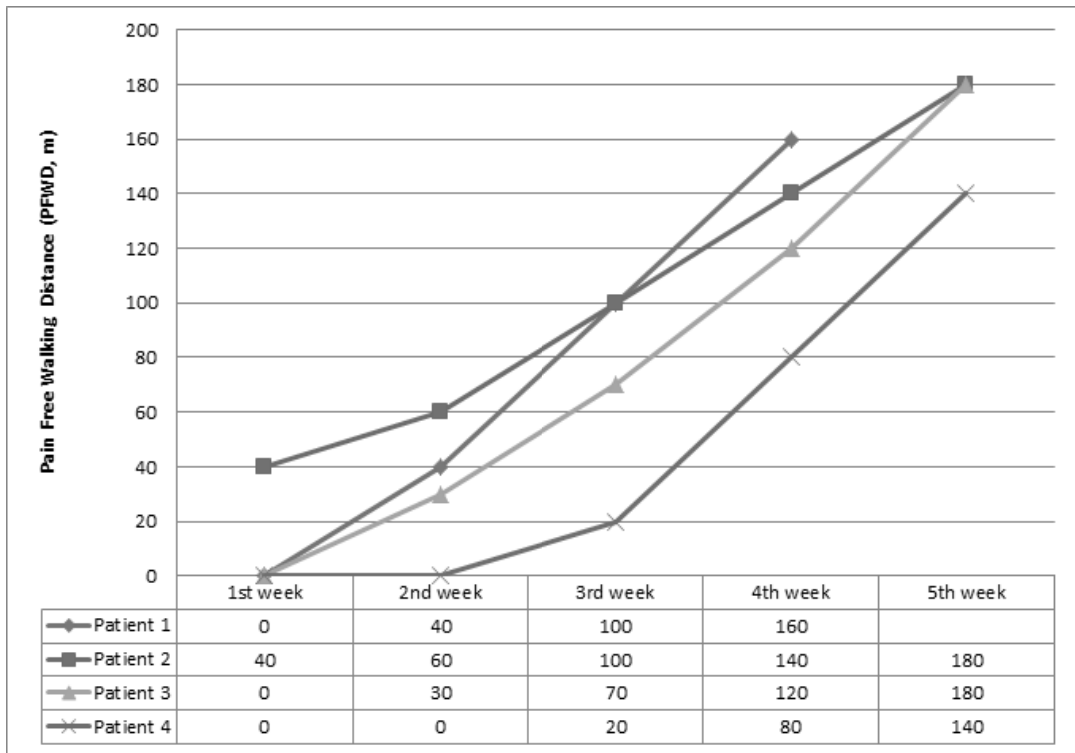


Fig. 7. Comparison of Pain Free Walking Distance(PFWD)

only able to analyze data during the average 4 weeks of admission treatment. Only the short-term effects of the treatment were shown and data after discharge was scarce and so it was unable to analyze the long-term effects. Second there is only small number of patient cases so we can only provide a limited result. Third, admission treatment was a combination of treatments and it is impossible to fully understand the effects of each treatment involved. It seems necessary to design additional studies for overcoming this limitation of this study.

There are many studies reporting the effects of Complex Korean Medical Treatment on Lumbar disc herniation or Spinal stenosis. However there were no studies regarding the effects of Complex Korean Medical Treatment in recurrent pain due to

FBSS after Fusion surgery with ASD. In this study, Four cases of patients showed improvement in pain, PFWD, and functional status after complex Korean Medicine treatment. In the future, rigorous randomized clinical trials should be designed to verify the clinical efficacy of Complex Korean Medical treatment.

References

1. Slipman CW, Shin CH, Patel RK, Isaac Z, Huston CW, Lipetz JS, et al. Etiologies of failed back surgery syndrome. *Pain Medicine*. 2002;3(3):200-214.
2. North RB, Campbell JN, James CS, Conover-Walker MK, Wang H, Piantadosi S, et al. Failed back surgery syndrome: 5-year follow-up

- in 102 patients undergoing repeated operation. *Neurosurgery*. 1991;28(5):685-90.
3. Waddell G, Kummel EG, Lotto WN, Graham JD, Hall H, McCulloch JA. Failed Lumbar Disc Surgery and Repeated Surgery following Industrial Injuries, *J. Bond and Joint Surg.* 1979;61(2):201-207.
 4. Cauchoix J, Ficat C, Girard B. Repeat surgery after disc excision. *Spine*. 1978;3(3):256-259.
 5. Javid MJ, Hadar EJ. Long-term follow-up review of patients who underwent laminectomy for lumbar stenosis: a prospective study. *J Neurosurg*. 1998;89(1):1-7.
 6. Pheasant HC, Dyck P. Failed lumbar disc surgery : cause, assesment, treatment. *Clinical Orthopaedics & Related Research*. 1982;164(4): 93-109.
 7. Cho E, Kang JH, Choi JY, Yoon KS, Lee H. The Clinical Study on Effects of Bee Venom Pharmacopuncture Therapy in Patients with FBSS(Failed Back Surgery Syndrome). *The Journal of Korean Acupuncture & Moxibustion Society*. 2011;28(5):77-86.
 8. Kim SP, Kim JH, Ryu HS, Chun HS, Shin JC. The Clinical Report on 1 Case of Failed Back Surgery Syndrome Who were Diagnosed as the Cauda Equina Syndrome using Hominis Placenta Pharmacopuncture. *The Journal of Korean Acupuncture & Moxibustion Society*. 2011;28(5):135-142.
 9. Ju MS, Jeong HU, Kim HG, Park GH, Youn YS, Kim YO, et al. Anti-nociceptive and anti-inflammatory effects of geranii herba. *Kor J Herbology*. 2010;25(3):97-101.
 10. Kim KO, Jeong YJ, Youn YS, Choi JC, Kim JH, Chung W, et al. Nonoperative Korean Medicine Combination Therapy for Lumbar Spinal Stenosis: A Retrospective Case-Series Study. *Evidence-Based Complementary and Alternative Medicine* 2015;501:263898.
 11. Roland M, Fairbank J. The Roland-Morris Disability Questionnaire and the Oswestry Disability Questionnaire. 2000;25(24):3115-3124.
 12. Ceccherelli F, Rigoni MT, Gagliardi G, Ruzzante L. Comparison of superficial and deep acupuncture in the treatment of lumbar myofascial pain: a double-blind randomized controlled study. *The Clinical journal of pain*. 2002;18(3):149-153.
 13. Brinkhaus B, Witt CM, Jena S, Linde K, Streng A, Wagenpfeil S, et al. Acupuncture in patients with chronic low back pain: a randomized controlled trial. *Archives of internal medicine*. 2006;166(4):450-457.
 14. Furlan AD, Van Tulder MW, Cherkin DC, Tsukayama H, Lao L, Koes BW, et al. Acupuncture and dry-needling for low back pain. *Cochrane Database Syst Rev* 1. 2005;1
 15. Zhao ZQ. Neural mechanism underlying acupuncture analgesia. *Progress in neurobiology*. 2008;85(4):355-375
 16. Kim KH, Kim SS. Study on analgesic, antiinflammatory and antipyretic effects of Aquaacupuncture and administration per orally of Whangryounhaedogtang (黃連解毒湯) and Onsungouhyoulbang (溫性瘀血方). *The Journal of Korean Oriental Medicine*. 1994;15(1):9-25.
 17. Winnie AP, Hartman JT, Meyers JR HL, Ramamurthy S, Barangan V. Intradural arid Extradural Corticosteroids for Sciatica. *Anesthesia & Analgesia*, 1972;51(6):990-1003.
 18. Pountain, GD, Keegan AL, Jayson MIV. Impaired fibrinolytic activity in defined chronic back pain syndromes. *Spine*. 1987;12(2):83-86.
 19. Heithoff KB, Burton CV. CT evaluation of the failed back surgery syndrome. *The Orthopedic clinics of North America*. 1985;16(3):417-444.
 20. Choi HS, Uhm BK, Kim CY, Han SW, Jung YG, Shin DJ. The Latest Trends of Chuna Treatment on Low Back Pain in PubMed. *J Oriental Rehab Med*. 2012;22(4):99-113.